

Hydatid Cyst of Left Atrioventricular Groove: An Unusual Presentation

MEENAKSHI SUNDARAM

ABSTRACT

Cardiac involvement in echinococcal infections is very rare. We are presenting here a case of hydatid cyst of the left atrioventricular groove in a middle aged female who presented

with breathlessness and chest pain. Echocardiography showed a cyst in the posterior atrioventricular groove. The cyst was excised on a cardiopulmonary bypass. The patient made an uneventful recovery.

Key Words: Hydatid cyst, Heart

CASE REPORT

A 35-year old mother of 2 children presented with complaints of breathlessness, chest pain and joint pain of 8 months duration. The breathlessness and chest pain increased on exertion. She was a known hypertensive and was on medications. She gave a history of giddiness and palpitation on and off. She was not a known asthmatic. On examination, her heart rate was found to be 76 minutes, her BP was 140/80mmHg and her JVP was not raised. She was not anaemic, jaundiced or cyanosed. Pedal oedema was absent. On auscultation, an ejection systolic murmur was heard in the mitral area. Her respiratory system was clear. The echocardiogram revealed moderate mitral regurgitation, mild dilatation of the left atrium and a cystic lesion in the left atrioventricular groove [Table/Fig-1]. A trans-oesophageal echocardiogram showed a cystic lesion in the left posterior atrioventricular groove with compressing and mild tethering of the posterior mitral leaflet, causing eccentric mitral regurgitation. The cystic lesion was irregularly calcified.

The patient underwent marsupialization of the cyst on the epicardial aspect of the left atrioventricular groove under a cardiopulmonary bypass. She was shifted to the ward on the second postoperative day and was discharged after seven days.

PATHOLOGICAL FINDINGS

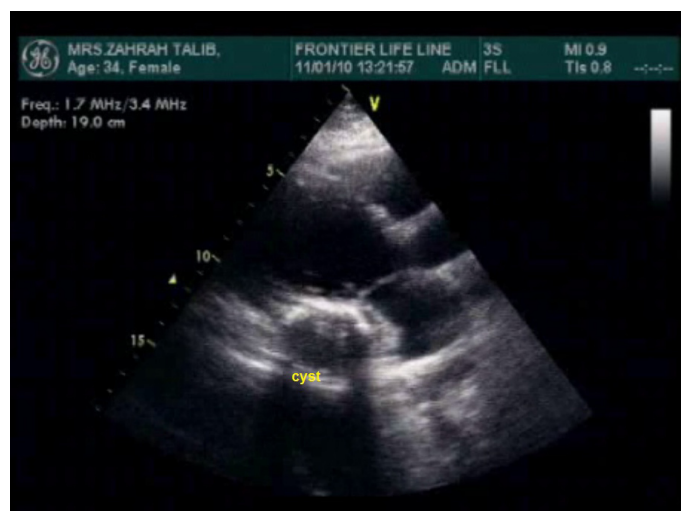The macroscopic examination showed irregular bits of cyst wall, the largest measuring 4x3x0.5cm. The external surface was smooth and the wall showed irregular calcification [Table/Fig-2] The inner surface was irregular.

The microscopic examination revealed the characteristic laminated membrane which was seen with the inner surface showing the scolex of echinococcus granulosus [Table/Fig-3 and 4].

DISCUSSION

Echinococcosis (hydatid disease, hydatidosis) is a zoonotic disease which is caused by the larval stages of cestodes which belong to the genus, *Echinococcus*. It is characterized by the long-term growth of metacestode (hydatid) cysts in intermediate hosts like human beings and herbivores like sheep, goats, cattle and pigs. The definitive hosts are carnivores such as dogs, wolves, and foxes [1].

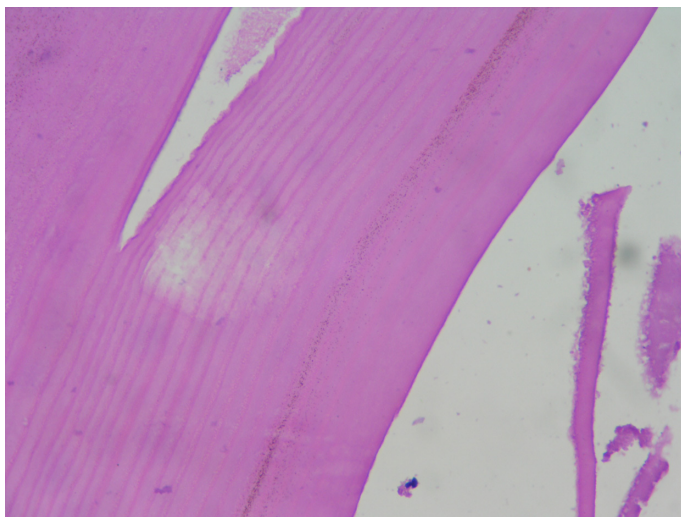
Swallowing of the eggs from canine faeces causes human infection. The embryos from the eggs pierce the intestinal wall, enter the portal circulation and reach liver where they develop into cysts. Few larvae bypass the liver and reach the lungs via the right heart. They can also reach the heart via the lymphatics, draining through



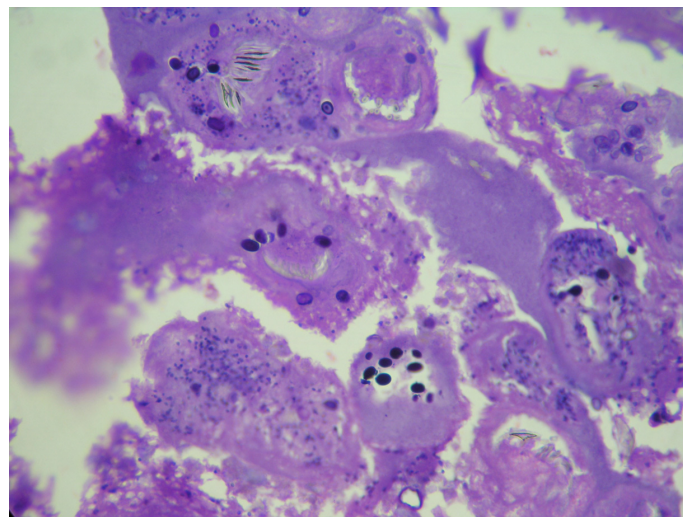
[Table/Fig-1]: Echocardiograph shows cyst in posterior atrioventricular groove



[Table/Fig-2]: Portions of cyst wall



[Table/Fig-3]: Microscopic picture shows laminated membrane. [H&E stain 10X]



[Table/Fig-4]: Microscopic picture shows scolex of *Echinococcus granulosus*. [H&E stain 40X]

the thoracic duct into the superior vena cava. They can reach other organs by gaining entrance into the systemic circulation. Hydatid cysts develop in the internal organs, mainly in the liver and the lungs.

Cardiac involvement is very rare and it develops in 0.5%–2% of the affected people. In the heart, the left ventricle is the common site which is affected and the left atrium is the least affected [2,3]. In our case, the left atrioventricular (AV) groove was involved.

Clinically, hydatid disease of the heart can present with ventricular outflow obstruction, causing low cardiac output and constrictive pericarditis. It can also present as a conduction disturbance when the interventricular septum is involved. Rarely, it can present as an anaphylactic shock following its rupture and with thromboembolism. Non-specific features like weight loss, fever and dyspnoea can be the presenting symptoms [3]. Our case presented with exertional dyspnoea.

Echocardiography, computerized tomography and magnetic resonance imaging are the investigation modalities which are available for these patients [4,5,6], Trans-oesophageal Echo and echocardiography revealed the cystic lesion in our case. Involvement of other organs was not seen in our case.

Removal of the cyst is the treatment of choice. Resection is recommended for intracardiac cysts, since their rupture produces fatal complications [7]. In our case, marsupialization of the calcified cyst was done on the epicardial aspect of the left AV groove under a cardiopulmonary bypass. She was advised oral albendazole

therapy following her discharge.

SUMMARY

The cardiac involvement is rare when it is compared with hepatic or pulmonary hydatidosis. The involvement of the heart can have a wide range of presentations. Two dimensional echocardiography is a diagnostic procedure which can demonstrate a cardiac hydatid cyst, with magnetic resonance imaging (MRI) being used more recently to diagnose hydatid cysts. Surgery is the treatment of choice, with additional oral albendazole therapy.

REFERENCES

- [1] Wenbao Zhang, Jun Li, Donald P. McManus, Concepts in Immunology and Diagnosis of Hydatid Disease, *Clinical microbiology reviews*, Jan. 2003; 18-36.
- [2] Dighiero J, Canabal EJ, Aguirre CV, Hazan J, Horjales JO. Echinococcus disease of the heart. *Circulation* 1958;17:127-32.
- [3] Heyat J, Mokhtari H, Hajjaliloo J, Shakibi G. Surgical treatment of echinococcal cyst of the heart. Report of a case and review of the world literature. *J Thorac Cardiovasc Surg* 1971;61:755-64.
- [4] Gulati G, Goyal NK, Kothari SS, Sharma S, Bisoi AK. Pericardial hydatid cyst. *Indian Heart J* 2002;54:437-38.
- [5] Oliver JM, Sotillo JF, Dominguez FJ, Lopez de Sa E, Calvo L, Salvador A, et al. Two-dimensional echocardiographic features of echinococcosis of the heart and the great blood vessels. Clinical and surgical implications. *Circulation* 1988;78:327-37.
- [6] Akar R, Eryilmaz S, Yazicioglu L, Eren NT, Durdu S, Uysalel A, et al. Surgery for cardiac hydatid disease: an Anatolian experience. *Anadolu Kardiyol Derg* 2003;3:238-44.
- [7] Shakibi JG, Safavian MH, Azar H, Siassi B. Surgical treatment of echinococcal cyst of the heart. Report of two cases and review of the world literature. *J Thorac Cardiovasc Surg* 1977;74:941-46.

AUTHOR(S):

1. Dr. Meenakshi Sundaram

PARTICULARS OF CONTRIBUTORS:

1. Associate Professor
Department of Pathology
Saveetha Medical College & Frontier Life Line Hospital
Chennai, Tamil Nadu, India.

NAME, ADDRESS, E-MAIL ID OF THE CORRESPONDING AUTHOR:

Dr. Meenakshi Sundaram
Associate Professor, Department of Pathology,
Saveetha Medical College and Frontier Life Line Hospital,
Thandalam, Chennai - 602105 (India).
Phone: 09444161999
E-mail: drkms75@gmail.com

FINANCIAL OR OTHER COMPETING INTERESTS:

None.

Date of Submission: **Dec 30, 2011**
Date of Peer Review: **Feb 25, 2012**
Date of Acceptance: **Mar 04, 2012**
Date of Publishing: **Aug 10, 2012**